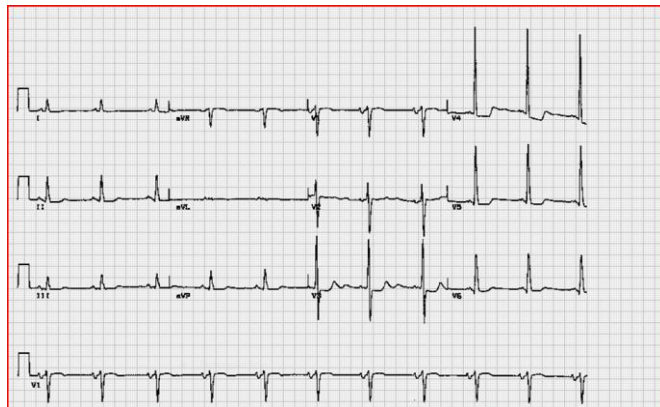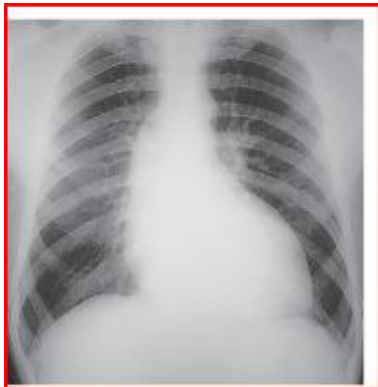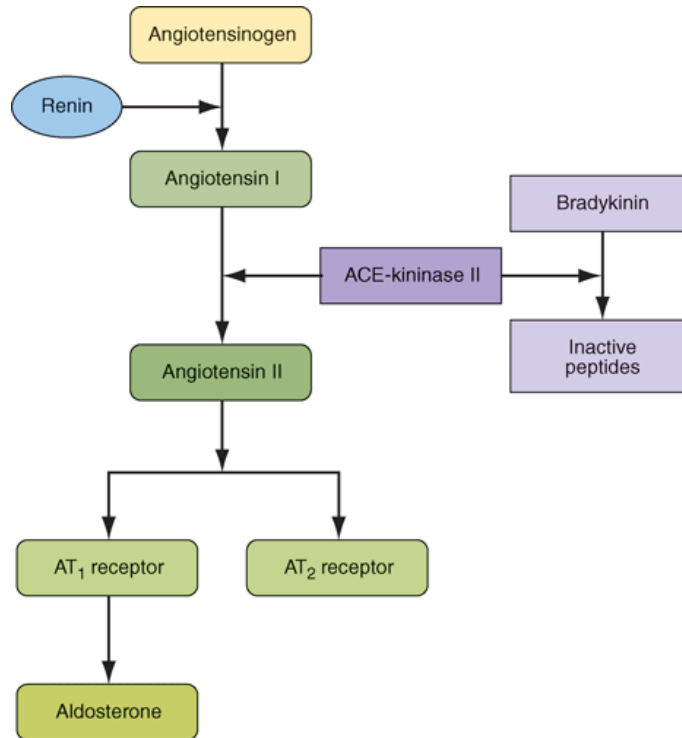


SBL - CVS Week 5

Hypertension-Case 1

- *40 years old male visited a clinic for executive checkup. He admitted having occasional episodic headache and chest pain on exertion. He has family history of Hypertension and is engaged in a stressful job. He smokes 10 cigarettes/day.*
- *Examination revealed obese adult with height of 150cm, weighing 100kg with BMI of 33, his BP was 160/100. Precordial examination was unremarkable. Follow up was advised after one week.*
- *His BP was checked on follow up visits and was found to be 150/96 to 160/100. His fasting blood glucose was 120mg/dl, cholesterol 240mg/dl, LDL 160mg/dl, HDL 35, VLDL 45mg/dl, triglycerides 290mg/dl, uric acid 7.4mg/dl, blood urea 40, creatinine 1 and normal electrolytes. Urine detailed report was normal. His ECG and X-ray chest PA view are shown in pictures.*





Source: Longo DL, Fauci AS, Kasper DL, Hauser SL, Jameson JL, Loscalzo J: *Harrison's Principles of Internal Medicine, 18th Edition*: www.accessmedicine.com
 Copyright © The McGraw-Hill Companies, Inc. All rights reserved.

Hypertension-Case 2

- 22 year old female presented in OPD with history of high blood pressure for 3 months, headache and joint pain for 1month. Examination revealed young lean built lady with height of 155cm and weight of 42kg, BP 170/110, Pulse 88/min, no radiofemoral delay, mild anemia, CVS examination revealed loud A2 and 4th heart sound. Abdominal examination revealed bruit above the umbilicus. Joint exam normal. Fundoscopy is shown in picture.

